

SAMRC InfoSpace

1. The detection and monitoring of early pregnancy in the vervet monkey (*Cercopithecus aethiops*) with the use of ultrasound and correlation with reproductive steroid hormones

Item Type	Article
Authors	Seier, J.V.;van der Horst, G.;de Kock, M.;Chwalisz, K.
Citation	J. V. S, G. van der H, M. de K, K. C. The detection and monitoring of early pregnancy in the vervet monkey (<i>Cercopithecus aethiops</i>) with the use of ultrasound and correlation with reproductive steroid hormones. Journal of Medical Primatology
Publisher	Medical primatology
Journal	Journal of Medical Primatology
Rights	Attribution 3.0 United States
Download date	2026-04-13 14:49:15
Item License	http://creativecommons.org/licenses/by/3.0/us/
Link to Item	https://infospace.mrc.ac.za/handle/11288/595242

The detection and monitoring of early pregnancy in the vervet monkey (*Cercopithecus aethiops*) with the use of ultrasound and correlation with reproductive steroid hormones

Seier JV, van der Horst G, de Kock M, Chwalisz K. The detection and monitoring of early pregnancy in the vervet monkey (*Cercopithecus aethiops*) with the use of ultrasound and correlation with reproductive steroid hormones. J Med Primatol 2000; 29:70–75. © Munksgaard, Copenhagen

Abstract: Twenty early pregnancies were diagnosed and monitored in vervet monkeys by ultrasonography. Non-gravid uteri became increasingly echogenic from cycle days 7 to 26. The first definite sign of pregnancy was a gestational cavity of 2 mm (± 0.80) at 33.0 (± 1.48) days menstrual age, which was also used to date all subsequent features. Earlier signs, such as an endometrial line swelling or endometrial 'pregnancy' ring, as reported for other non-human primate species, could not be reliably and consistently used to diagnose pregnancy in vervet monkeys. A rapid increase of the gestational cavity size from days 37 to 49 corresponded closely to a rapid increase in plasma progesterone concentration from day 39 to 49. The first yolk sac was recognizable at 38.0 days (± 3.10) and measured 3.3 mm (± 0.40) in diameter. A heart beat could be detected at 45.5 (± 1.73) days and the size of the first measurable embryo at 35 days was 2 mm. The dating of most features was within the range reported for other non-human primate species.

J.V. Seier¹, G. van der Horst²,
M. de Kock², K. Chwalisz³

¹Primate Unit, Experimental Biology Programme/MRC, P.O. Box 19070, Tygerberg 7505, South Africa, ²University of the Western Cape, Department of Physiological Sciences, Bellville, South Africa, ³Jenapharm and Co. KG, Jena, Germany

Key words: African green monkey – conception rate – fetal growth – timed matings – steroid hormones

Accepted October 5, 1999.

Jürgen Seier, Primate Unit, Experimental Biology Programme, P.O. Box 19070, Tygerberg 7505, South Africa.
E-mail: jurgen.seier@mrc.ac.za

Introduction

Gynaecological and obstetrical ultrasonography has become an indispensable tool in the routine management of non-human primate breeding, health and reproductive research. Pregnancy can be diagnosed earlier and easier than with a chorionic gonadotropin assay or rectal palpation [6, 12]. Many facilities do not have specific chorionic gonadotropin assays available and in these situations ultrasonography is particularly valuable. Moreover, chorionic gonadotropin of non-human primates may only be detectable during a very short time in early pregnancy, thereby limiting its use for pregnancy diagnosis in these species [6]. Because of the advantages of ultrasonography, it has been used in a variety of non-human primates [4, 9, 14, 16, 17]; however, no data appear to be available for vervet monkeys to date, and pregnancy has previously been determined only by rectal palpa-

tion [12]. There is evidence that organogenesis occurs later in the vervet monkey than in other non-human primate species [7] and this, as well as species specific differences, may influence the ultrasonographic appearance of reference features. This, in turn, could prevent extrapolation from other species to vervet monkeys.

This paper describes the use of ultrasound for the detection and monitoring of early pregnancy in vervet monkeys. The aim was to establish key diagnostic features that allow early diagnosis as well as timing and monitoring of pregnancy. Some of these features were related to plasma steroid concentrations and profiles. The results were expected to not only benefit breeding management, but also reproductive research in our facility, in that they would enable early intervention and definite diagnosis of the day of pregnancy termination.

Materials and methods

Animals

The females used were all multiparous, more than 5 years old and caged individually for the duration of the study. The housing conditions have been described previously [12, 13]. To produce timed matings, adult females were paired from cycle days 7 to 22, until 20 pregnancies were achieved. Menstruation was determined by daily vaginal swabbing with a cotton-tip applicator. Day 1 of menstruation was designated day 1 of the menstrual cycle. The overall conception rate for the timed matings was 45%; therefore, a total of 44 females were mated, of which 24 did not conceive.

The menstrual cycle length of vervet monkeys is reported to be about 32 days [3], and the gestation period about 157 days [8].

Ultrasonography and study design

Ultrasonography was performed on cycle days 7 and 22, as well as every second day from day 26 until the first positive diagnosis of pregnancy. Thereafter, images were taken 1, 2, 4, 6, 11 and 16 days after the first pregnancy diagnosis and were identified in terms of the menstrual age. If pregnancy, for example, was diagnosed on menstrual cycle day 34, 16 days later this was identified as menstrual age 50. Except in four cases, all pregnancies had to be terminated for a reproductive study 16 days after diagnosis.

Pregnancies were confirmed and monitored using an Aloka SSD-210DXII real-time electronic linear scanner equipped with a 7.5 MHz scanhead. Prints were produced with a thermal printer (Sony videographic printer UP-860 CE, Japan). To obtain ultrasonographs and blood, females were sedated lightly with ketamine hydrochloride at 5 mg/kg bodyweight and manually restrained. After placing in dorsal recumbence, the abdomen was shaved and covered with a thick layer of ultrasound gel (Hydrosonic ultrasound gel, IEM Products, South Africa). A gloved right index finger was inserted into the rectum to elevate the uterus towards the abdominal wall. Without this proce-

dure it was impossible to obtain images in all cases. The scanhead was placed in contact with the abdomen and, if necessary, the uterus could be manipulated into the most suitable position with the inserted index finger. Where possible, the following measurements were taken with the aid of the machine's electronic calipers:

- ventro-dorsal diameter of the gestational cavity,
- diameter of the yolk sac,
- length of the embryo,
- biparietal diameter.

The first appearance of the yolk sac and heart beat as well as the echogenicity of the uterus during the menstrual cycle were also recorded. The echogenicity during the cycle was obtained from the 24 females that did not conceive. The echogenicity was rated as follows:

- 0 = Black (hypoechogetic)
- ± = Black-dark grey (weakly echogenic)
- + = Dark grey (moderately echogenic)
- + + = Light grey-white (hyperechogenic)

Hormone analysis

Blood was taken for estradiol 17β (E₂) and progesterone analysis at the same time as the ultrasonographs. Both hormones were measured by specific radio-immunoassay; E₂ by using an antibody developed in-house and progesterone by solid-phase radio-immunoassay ('Coat a count', Diagnostics Products Corporation) as described previously [13].

Results

Clear ultrasonographic images of the uterus during the menstrual cycle and pregnancy were produced and some cyclic changes could be observed. On cycle day 7, which represents the proliferative phase, the endometrial interface was recognizable as a thin, often faint, hyperechoic line, bisecting the uterus. The uterus appeared hypoechogetic and the endometrial-myometrial border could mostly not be distinguished (Table 1, Fig. 1).

By day 22 the uterus appeared more echogenic and better defined with a clearer endometrial interface (Table 1, Fig. 2). No additional changes were apparent by day 26, except increasing echogenicity and an endometrial-myometrial border that could be better distinguished (Table 1). A distinct hyperechoic endometrial ring appeared at the level of the endometrial basalis by days 28-30 (Fig. 3). This ring occurred in 57.1% of non-pregnant and 31.3% pregnant females and was bisected by the endometrial interface.

Table 1. Uterine echogenicity rating during the cycle (% of 24 females)

Cycle day	Rating			
	0	±	+	++
7	40	25	35	0
22	5	60	35	0
26	0	15	60	20

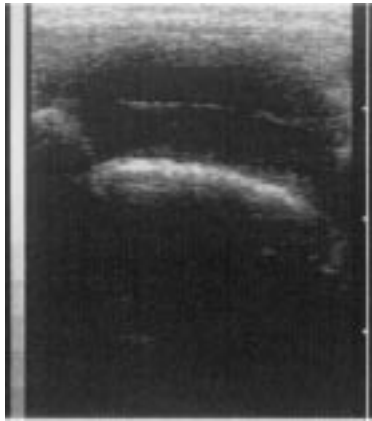

Fig. 1. Proliferative phase day 7. The endometrial–myometrial interface cannot be distinguished. The uterus is hypoechoic with an endometrial interface recognizable as a white line bisecting the uterus.

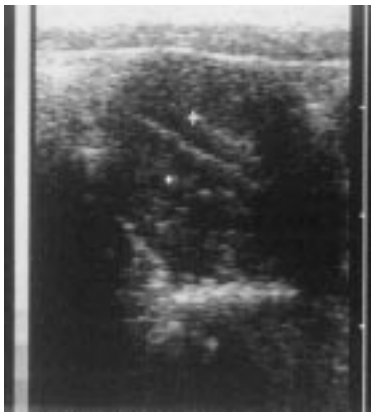

Fig. 2. Secretory phase day 22. The endometrial–myometrial interface is recognizable (between + calipers). The myometrium is more echogenic.

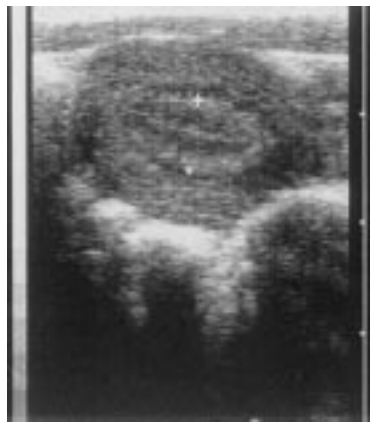

Fig. 3. Secretory phase day 28. There is a strong endometrial ring (+ calipers). The entire uterus is more echogenic.

The first diagnosis of pregnancy was possible between 30 and 35 days and the pregnant uterus appeared as a small, round hypoechoic cavity measuring about 2 mm (Table 2, Fig. 4). No other

diagnostic feature, such as a line swelling, could be consistently detected before this time. The gestational cavity doubled in size after about 4 days and Fig. 7 illustrates the increase of the gestational cavity during early pregnancy. It can be seen that there is more rapid growth from 37 to 39 days. Some key diagnostic features are provided in Table 2 and Figs. 5 and 6 illustrate the appearance of fetuses at 45 and 51 days menstrual age. The earliest conceptus could be measured at 35 days menstrual age and was 2 mm in length. The biparietal diameter increased from 10 to 20 mm within 3 weeks from week 10.

The progesterone and estradiol profiles are provided in Figs. 8 and 9, respectively. The mean concentration of progesterone declined from days 34 to 37, then sharply increased again from day 39 and appeared to reach a plateau by day 49. Apart from a moderate increase on days 33 and 34, there appeared to be no change in estradiol 17β concentrations during the sampling period.

Discussion

Certain important ultrasonographic reference features, the appearance of cyclic uterine changes and early pregnancy were readily identified in the vervet monkey. These included the endometrial interface from which key changes take place, enabling early pregnancy diagnosis [1, 11, 16]. However, modification of the scanning technique, consisting of pushing the uterus towards the scanhead, was necessary to achieve ultrasonographic images. This has not been reported before and appeared to have not been necessary in other species [1, 11, 16]. The short focus of the 7.5 MHz scanhead, when compared with the 5 MHz type frequently used in non-human primates [1, 14], might have been partially responsible for the need for modification in some cases. On the other hand, 7.5 MHz scanheads were used on cynomolgus and rhesus monkeys without the need for elevating the uterus [10, 16].

The appearance of the uterus during the cycle was similar to that of other primate species including humans, with increased reflectivity during the secretory phase [5, 10, 11]. Unlike cynomolgus monkeys [1], but similar to women [10], a distinct hyperechoic endometrial ring observed in the basalis region was not diagnostic of pregnancy in vervet monkeys. No such ring-like structure could be observed in rhesus monkeys [10].

Another difference between vervet monkeys and cynomolgus monkeys was that a line swelling in the endometrial interface [1] could not be reliably and consistently detected in early pregnant vervet monkeys. Our study shows that the earliest posi-

Table 2. Key diagnostic features of vervet monkey pregnancy

	Mean	Range	±SD	n
Menstrual age at first definite diagnosis of pregnancy (days)	33.1	30–35	1.48	20
Ventro-dorsal diameter of gestational cavity at first diagnosis (mm)	2	1–4	0.80	20
Menstrual age at first visualization of the yolk sac (days)	38.0	32–41	3.10	20
Size of yolk sac at first visualization (mm)	3.3	3–4	0.40	20
Menstrual age at first detectable heart beat (days)	45.5	44–48	1.73	4
Menstrual age of first measurable embryo	35.0	–	–	1
Size of first measurable embryo (mm)	2	–	–	1
Biparietal diameter at 9 weeks (mm)	10	9–11	0.80	4
Biparietal diameter at 12 weeks (mm)	20	17–22	0.21	4

tive identification of pregnancy in this species remained a small hypochoic gestational cavity within the endometrial interface as in Japanese macaques [14].

The detection of early pregnancy in vervet monkeys was consistent within a narrow period of time of 30–35 days menstrual age. This is in contrast to the cynomolgus monkey in which early detection was highly variable ranging from 11 to 34 days gestational age, which was believed to be due to the irregular timing of the first ultrasound examinations [1, 14, 16]. Because of this variability in cynomolgus monkeys, the onset of organogenesis, in terms of ultrasonographic appearance, between the former species and vervet monkeys cannot be compared. Because a short 7.5 MHz scanhead was used in our study, the dorso-ventral diameter was measured. This was found to be an equally satisfactory indicator of fetal growth as the cavity length measured by Shimizu [14].

The rapid increase of the gestational cavity observed from day 37 (about 23 days gestation) was close to the start of organogenesis in vervet monkeys, which, similar to humans [7], takes place around day 21 of pregnancy [7]. The first definite diagnosis of vervet monkey pregnancy was at 33.1 days menstrual age, which represents about 20 days gestation when considering a follicular phase of about 13 days for this species [8]. This supports the finding of Hendrickx et al. [7] of a later onset of organogenesis in vervet monkeys when compared with other non-human primate species.

Interestingly, the above-mentioned rapid increase of the gestational cavity was accompanied by a rapid increase of serum progesterone concentrations, which may represent the shift of progesterone secretion from the ovary to the placenta. This also occurs around 21–27 days in rhesus monkeys [15]. Early pregnancy detection in vervet monkeys clearly falls within the range reported for cynomolgus monkeys which is between 11 and 34 days gestational age [1, 14, 16]. This is between 25.4 and 48.4 days menstrual age, which is calcu-

lated by adding a follicular phase of about 14.4 days reported for cynomolgus monkeys [2]. The earliest yolk sac could be detected in cynomolgus monkeys at 21–25 days or 35.4–39.4 days menstrual age [16] which is similar in vervet monkeys with a mean of 38.0 days.

The timing of the first detectable heart beat in vervet monkeys also falls within the range reported for cynomolgus monkeys, which is 21–30 days or

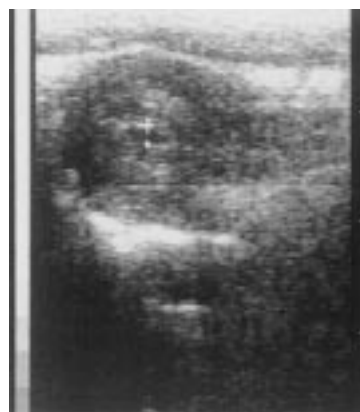

Fig. 4. The first sign of pregnancy is a gestational cavity of about 2 mm (+ calipers) from between the endometrial interface. In this example 34 days after the onset of menstruation.

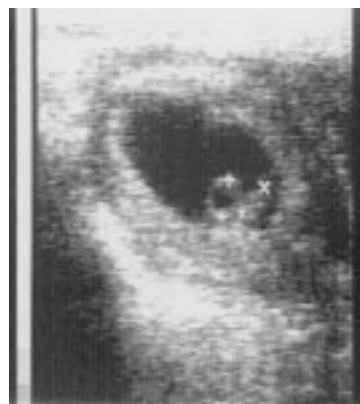

Fig. 5. Conceptus measuring 3 mm (× calipers) and yolk sac measuring 3 mm (+ calipers) 45 days after the onset of menstruation. The first heart beat is detectable around this time.

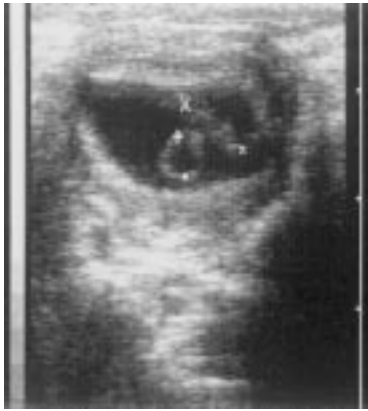

Fig. 6. A fetus measuring 7 mm (+ calipers) and a yolk sac of 4 mm (× calipers) diameter, 51 days after the onset of menstruation.

34.4–44.4 menstrual age [1, 16]. The age of the first measurable embryo in vervet monkeys and cynomolgus monkeys [1, 16] is 35 and 34.4 days (21 days gestation), respectively, and therefore sim-

ilar in both species. At this age the crown-rump length was 2 mm in both species [1]. These observations can, however, not be generalized since, in our study and one of the above-mentioned [1], only one embryo was measured. In the second above-mentioned study [16] it is unclear how many embryos were investigated. The biparietal diameter for gestational age as well as a rapid skull growth of vervet monkeys also compared well with *Macaca fascicularis* and *Macaca fuscata* [14].

The progesterone profile of vervet monkeys during early pregnancy appears similar to that of cynomolgus monkeys, although in the latter it declined from about day 30 (44.4 menstrual age) until day 50 [6]. The estradiol profile appeared stable in cynomolgus monkeys until about day 35 (menstrual age 49.4 days), which was also observed in this study with vervet monkeys.

The conception rate for vervet monkeys during the timed matings was similar to that of *Macaca fascicularis*, which is reported to be 43.9% [1]. In

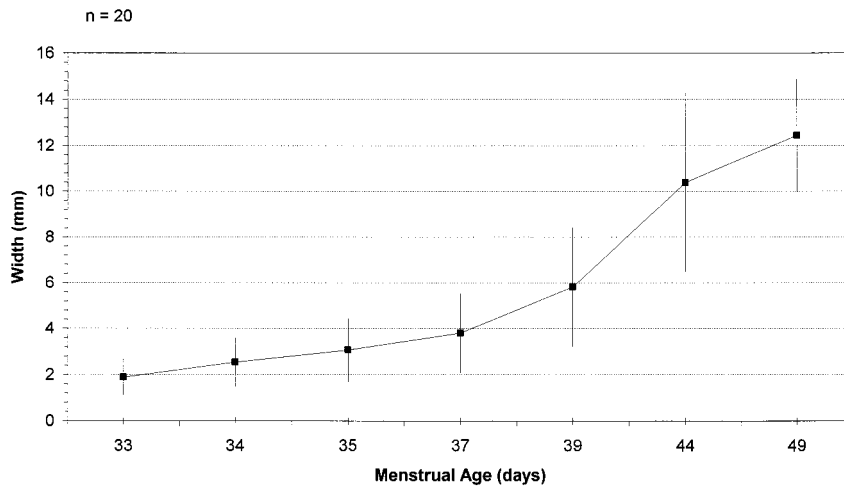


Fig. 7. Mean increase (\pm SD) of the ventro-dorsal diameter of the gestational cavity during early pregnancy.

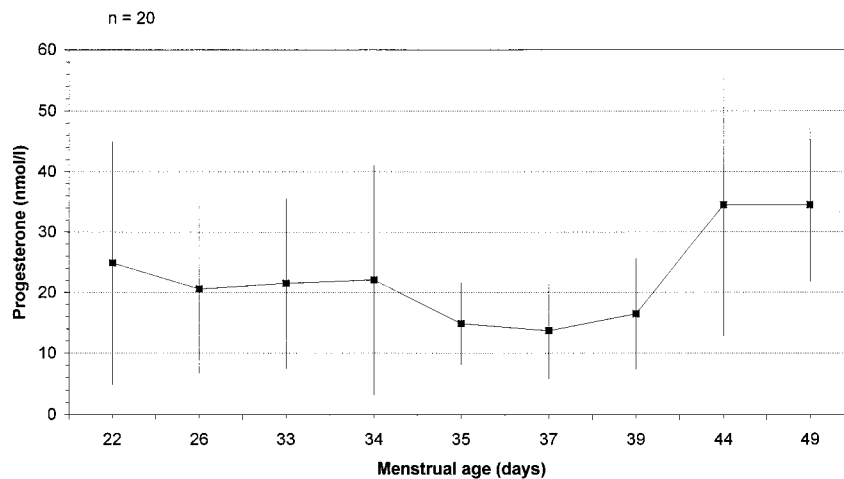


Fig. 8. Mean plasma progesterone concentrations (\pm SD) during early pregnancy.

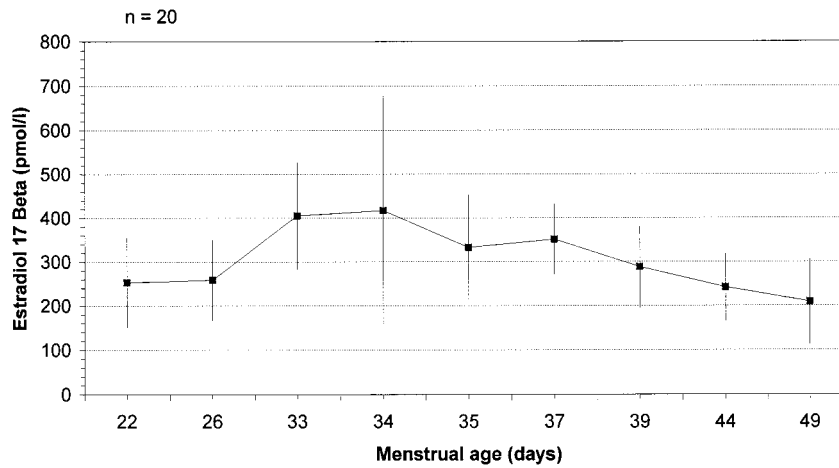


Fig. 9. Mean plasma estradiol 17β concentrations (±SD) during early pregnancy.

conclusion, the data obtained in this study not only provide important key features for the diagnosis and monitoring of pregnancy, but also show that early pregnancy in the vervet monkey, as defined by certain ultrasonographic features, proceeds similarly to other non-human primate species.

References

1. CONRAD SH, SACKETT GP, BURBACHER M: Diagnosis of early pregnancy by ultrasound *Macaca fascicularis*. *J Med Primatol* 18:143–154, 1989.
2. DUKELOW RW, BRÜGGEMAN S: Characteristics of the menstrual cycle in nonhuman primates II. Ovulation and optimal mating times in macaques. *J Med Primatol* 8:79–87, 1979.
3. ELEY RM, TARARA RP, WORTHMAN CM, ELSE JG: Reproduction in the vervet monkey (*Cercopithecus aethiops*): III the menstrual cycle. *J Med Primatol* 17:1–10, 1989.
4. FARINE D, MACCARTER GD, TIMOR-TRITCH IE, YEH MN, STARK RI: Real-time ultrasonic evaluation of the baboon pregnancy: biometric measurements. *J Med Primatol* 17:215–221, 1988.
5. FOSTER WG, STALS SI, MCMAHON A: A prospective analysis of endometrial cycle changes by ultrasound in the female cynomolgus monkey. *J Med Primatol* 21:30–34, 1992.
6. HEIN PR, SCHATORJE JSJO, FRENCKEN HJAAM, SEGERS MFG, THOMAS CMG: Serum hormone levels in pregnant cynomolgus monkeys. *J Med Primatol* 18:133–142, 1989.
7. HENDRICKX AG, SAWYER RH, LASLEY BL, BARNES RD: Comparison of development stages in primates with a note

- on the detection of ovulation. In: Perkins FT, O'Donoghue PN (eds). *Breeding Simians for Developmental Biology*. Laboratory Animal Handbook 6. Laboratory Animals Ltd: London 305–316, 1975.
8. HESS DL, HENDRICKX AG, STABENFELDT GH: Reproductive and hormonal patterns in the African green monkey (*Cercopithecus aethiops*). *J Med Primatol* 8:273–281, 1979.
9. LÖGDBERG B: Methods for timing of pregnancy and monitoring of fetal body and brain growth in squirrel monkeys. *J Med Primatol* 22:374–379, 1993.
10. MORGAN PM, HUTZ RJ, KRAUS EM, BAVISTER BD: Ultrasonographic assessment of the endometrium in rhesus monkeys during the normal menstrual cycle. *Biol Reprod* 36:463–469, 1987.
11. SAKAMOTO C: Sonographic criteria of phasic changes in human endometrial tissue. *Int J Gynaecol Obstet* 23:7–12, 1985.
12. SEIER JV: Breeding vervet monkeys in a closed environment. *J Med Primatol* 15:339–349, 1986.
13. SEIER JV, VENTER FS, FINCHAM JE, TAJJAARD JJF: Hormonal vaginal cytology of vervet monkeys. *J Med Primatol* 20:1–5, 1991.
14. SHIMIZU K: Ultrasonic assessment of pregnancy and fetal development in three species of macaque monkeys. *J Med Primatol* 17:247–256, 1988.
15. STOFFER RIL, OTTOBRE JS, VANDEVOORT CA: Regulation of the primate corpus luteum during early pregnancy. In: Stouffer RL (ed). *The Primate Ovary*. Serono Symposium USA. Plenum Press: New York 207–220, 1987.
16. TARANTAL AF, HENDRICKX AG: Use of ultrasound for early pregnancy detection in the rhesus and cynomolgus macaque (*Macaca mulatta* and *Macaca fascicularis*). *J Med Primatol* 17:105–112, 1988.
17. TARANTAL AF: Sonographic assessment of nonpregnant female macaques (*Macaca mulatta* and *Macaca fascicularis*). *J Med Primatol* 21:308–315, 1992.

Copyright of Journal of Medical Primatology is the property of Blackwell Publishing Limited and its content may not be copied or emailed to multiple sites or posted to a listserv without the copyright holder's express written permission. However, users may print, download, or email articles for individual use.

Copyright of Journal of Medical Primatology is the property of Wiley-Blackwell and its content may not be copied or emailed to multiple sites or posted to a listserv without the copyright holder's express written permission. However, users may print, download, or email articles for individual use.