

White matter volume alterations in hair-pulling disorder (trichotillomania)

Item Type	Article
Authors	Uhlmann, A;Dias, A;Taljaard, L;Stein, D.J;Brooks, S.J;Lochner, C
Citation	Uhlmann A, Dias A, Taljaard L, Stein DJ, Brooks SJ, Lochner C. White matter volume alterations in hair-pulling disorder (trichotillomania). Brain Imaging and Behavior. 2019 Aug 2. doi: 10.1007/s11682-019-00170-z
Publisher	Springer Nature
Journal	Brain Imaging and Behavior
Rights	Attribution 3.0 United States
Download date	2024-12-09 23:40:43
Item License	http://creativecommons.org/licenses/by/3.0/us/
Link to Item	https://doi.org/10.1007/s11682-019-00170-z



White matter volume alterations in hair-pulling disorder (trichotillomania)

Anne Uhlmann^{1,2} · Angelo Dias² · Lian Taljaard¹ · Dan J. Stein² · Samantha J. Brooks^{2,3} · Christine Lochner¹ 

Published online: 2 August 2019

© Springer Science+Business Media, LLC, part of Springer Nature 2019

Abstract

Trichotillomania (TTM) is a disorder characterized by repetitive hair-pulling resulting in hair loss. Key processes affected in TTM comprise affective, cognitive, and motor functions. Emerging evidence suggests that brain matter aberrations in fronto-striatal and fronto-limbic brain networks and the cerebellum may characterize the pathophysiology of TTM. The aim of the present voxel-based morphometry (VBM) study was to evaluate whole brain grey and white matter volume alteration in TTM and its correlation with hair-pulling severity. High-resolution magnetic resonance imaging (3 T) data were acquired from 29 TTM patients and 28 age-matched healthy controls (CTRLs). All TTM participants completed the Massachusetts General Hospital Hair-Pulling Scale (MGH-HPS) to assess illness/pulling severity. Using whole-brain VBM, between-group differences in regional brain volumes were measured. Additionally, within the TTM group, the relationship between MGH-HPS scores, illness duration and brain volumes were examined. All data were corrected for multiple comparisons using family-wise error (FWE) correction at $p < 0.05$. Patients with TTM showed larger white matter volumes in the parahippocampal gyrus and cerebellum compared to CTRLs. Estimated white matter volumes showed no significant association with illness duration or MGH-HPS total scores. No significant between-group differences were found for grey matter volumes. Our observations suggest regional alterations in cortico-limbic and cerebellar white matter in patients with TTM, which may underlie deficits in cognitive and affective processing. Such volumetric white matter changes may precipitate impaired cortico-cerebellar communication leading to a reduced ability to control hair pulling behavior.

Keywords Trichotillomania · Compulsivity · Impulsivity · Neuroimaging · Voxel-based morphometry

Introduction

Individuals with trichotillomania (TTM, or hair-pulling disorder) recurrently pull out hair, resulting in hair loss and feelings of shame and embarrassment. The condition is associated with significant distress and/or impaired functioning in several

domains (American Psychiatric Association 2013; Woods et al. 2006). Recently, TTM was reclassified from an impulse control disorder in DSM-IV-TR to an obsessive-compulsive and related disorder (OCRD) in DSM-5, but it is possible that both impulsivity and compulsivity may underlie its psychopathology (Flessner et al. 2012). In addition to the stereotyped motor routines characteristic of TTM, a psychobiological model proposes deficits in affect regulation, cognitive control, and behavioral addiction as further key domains (Stein et al. 2006). While the aetiology of TTM is not fully elucidated, there is emerging evidence for genetic and environmental underpinnings as well as neural correlates, such as brain regions involved in affect regulation, top-down cognition, and motor control.

Available functional neuroimaging data in individuals with TTM is scarce, but so far suggests that aberrations in fronto-striatal and fronto-limbic brain networks and the cerebellum may underlie pathophysiology (Grant and Chamberlain 2016). Findings of structural grey matter abnormalities in these networks are however inconsistent, with some studies reporting

Electronic supplementary material The online version of this article (<https://doi.org/10.1007/s11682-019-00170-z>) contains supplementary material, which is available to authorized users.

✉ Christine Lochner
cl2@sun.ac.za

¹ MRC Unit on Risk and Resilience in Mental Disorders, Department of Psychiatry, Stellenbosch University, PO Box 241, Cape Town 8000, South Africa

² Department of Psychiatry and Mental Health, University of Cape Town, Cape Town, South Africa

³ Department of Neuroscience, Uppsala University, Uppsala, Sweden

smaller volumes in cerebellum, amygdala, putamen and frontal gyrus, lower parahippocampal thickness as well as larger cuneus volume, and higher grey matter density in the striatum, amygdalo-hippocampal formation, and cingulate and frontal cortices in TTM compared to healthy controls (Chamberlain et al. 2008, 2018; Grachev 1997; Isobe et al. 2018; Keuthen et al. 2007a; O’Sullivan et al. 1997; Roos et al. 2015). In contrast, other studies did not find structural grey matter differences between TTM and healthy controls in striatal or cerebellar regions (Odlaug et al. 2014; Stein et al. 1997).

Although white matter also constitutes these distributed neural networks connecting cortical, subcortical and cerebellar brain regions, alterations in white matter are understudied in TTM. The first assessments of white matter density have not revealed any significant group differences between TTM patients and healthy controls (Chamberlain et al. 2008). However, emerging evidence from a diffusion tensor imaging (DTI) study showed diminished white matter microstructure in TTM compared to healthy controls in the anterior cingulate, orbitofrontal, and primary somatosensory cortices, the temporal lobe, and supplementary motor area (Chamberlain et al. 2010). Although a subsequent study did not replicate these findings, presumably due to the smaller sample size and resulting lower power, it reported a relationship between white matter integrity in fronto-striatal-thalamic pathways and TTM symptom duration and severity (Roos et al. 2013).

To advance existent knowledge regarding structural neural correlates of TTM, the present study investigated grey and white matter volumetric differences between individuals with TTM and healthy controls, using voxel-based morphometry (VBM). We hypothesized structural abnormalities in fronto-limbic-striatal and cerebellar volumes in TTM.

Methods

Participants and procedures

The study comprised of adult patients with a primary diagnosis of TTM ($n = 29$), and healthy controls (CTRL; $n = 28$). All participants were right-handed. Participants with a history of significant substance or alcohol abuse, psychosis, neurological illness, head trauma, or a contraindication to MRI were excluded from participation. Additionally, CTRLs were excluded if they had any current DSM-IV-TR disorder.

The protocol was approved by the Health Research Ethics Committee at Stellenbosch University (HREC Ref. M07/05/019) and the Human Research Ethics committee of UCT (HREC Ref. 261/2007), and after a detailed description of the study, all participants provided written informed consent.

Participants were recruited by means of newspaper, poster and online advertisements, and referrals by psychologists and psychiatrists in the Cape Town area. They were screened

telephonically and subsequently interviewed by a clinical psychologist at the MRC Unit on Risk and Resilience in Mental Disorders, Department of Psychiatry, Stellenbosch University. Patients with problematic hair-pulling were included, which was confirmed by completing the structured clinical interview for obsessive-compulsive spectrum disorders (SCID-OCSD; du Toit et al. 2001). The Mini International Neuropsychiatric Interview Plus (MINI Plus) - version 5 (Sheehan et al. 1998), a structured diagnostic interview developed for DSM-IV and ICD-10 psychiatric disorders, was further used to assess comorbidity. Severity of TTM symptoms was assessed using the Massachusetts General Hospital Hair-pulling Scale (MGH-HPS; Keuthen et al. 1995) which comprises seven questions assessing behaviors and feelings over the past week, providing a total hair-pulling score as well as two factor scores for severity and resistance/control (Keuthen et al. 2007b). The Clinical Global Impressions Scale (CGI; Busner and Targum 2007) was administered to assess the patient’s current global functioning. Illness duration (in years) was also logged.

MRI image acquisition and processing

All participants underwent a whole-brain scan at one of two imaging centres in Cape Town. All CTRL and 17 of the TTM scans (58.6%) were acquired using a 3 T Siemens Allegra scanner at the Cape Universities Brain Imaging Centre at Stellenbosch University, South Africa. Here, a high-resolution, T1-weighted, 3D-MPRAGE sequence was used with the following scan parameters: TR = 2300 ms; TE = 3.93 ms; flip angle = 12°; FOV = 480x512x160mm, voxel size = 0.5 × 0.5x1mm.

After this imaging centre was closed permanently, the remaining 12 TTM scans were acquired using a 3 T Siemens Skyra scanner at the new Cape Universities Body Imaging Centre at the University of Cape Town, using a 3D-multi echo MPRAGE sequence with the following scan parameters: TR = 2530 ms; graded TE = 1.53, 3.21, 4.89, 6.57 ms; flip angle = 7°; FOV = 256x256x160mm; voxel size = 1x1x1mm. Potential confounds of scan differences were considered, as specified in the statistical analysis section.

Image processing steps and VBM analyses were conducted using the computational anatomy toolbox (CAT12) in SPM12 (Statistical Parametric Mapping). All nifti-converted T1 images were manually reoriented into the AC-PC plane, and initial visual quality check for signal artefacts was done. In one automated analysis step, T1 images were normalized to a high-dimensional Diffeomorphic Anatomical Registration Through Exponentiated Lie algebra (DARTEL) template in MNI space (Ashburner 2007), and segmented into grey matter, white matter, and cerebrospinal fluid (CSF). After pre-processing, images were quality checked again, both visually and computationally with an integrated CAT12 module for sample homogeneity assessment and outlier identification. Before entering the images into a statistical model, image data

were smoothed with an 8 mm ‘Full Width Half Maximum’ (FWHM) Gaussian kernel to reduce noise.

Statistical analysis

Statistical analysis of sample characteristics was performed using IBM SPSS 24. Assumption of normality of each variable was tested with the Shapiro-Wilk test, with non-parametric tests employed in instances where this assumption was violated. The TTM and CTRL study groups were compared across demographic variables using Mann-Whitney *U* and chi-square tests, as appropriate. Independent *t*-tests were used for comparison of global brain matter volumes and CSF, as data were normally distributed. For all analyses, *p*-values <0.05 were considered statistically significant.

VBM analyses of grey and white matter volumetric differences between TTM patients and CTRLs were performed in SPM12. A general linear model (GLM) was set up with age (log transformed) and total intracranial volume (TIV) added as covariates to adjust for potential confounding effects on brain volumetric analyses. Gender was not included as a covariate based on its exceedingly skewed distribution in both groups (males: 3% in TTM; 43% in CTRL). As TTM patients were scanned on two different scanners, we repeated the analysis including only study participants with the same scan acquisition at Stellenbosch University (TTM: *n* = 17, CTRL: *n* = 28). Further, to rule out a potential gender influence on significant

results, we conducted a second follow-up analysis including only female participants in the cohort scanned at Stellenbosch University (TTM: *n* = 17, CTRL: *n* = 16).

To model positive and negative associations between brain matter volume and illness duration, MGH-HPS scores (total score and factor scores for severity and resistance/control) as well as individual hair-pulling ratings of interest from this scale (including control over hair-pulling, frequency of hair-pulling, associated distress, and attempts to resist pulling), multiple regression models were created for the TTM group. These models were covaried for age, TIV, and differences in scan parameters. Family-wise error (FWE) corrected results meeting a voxel threshold empirically determined in each analysis (see Results) are reported.

Results

Demographics

Demographic characteristics of the two study groups are summarized in Table 1. Statistical analysis revealed no significant group differences in age and education level or in overall volumes of brain matter and cerebrospinal fluid. However, gender and ethnicity distribution differed between groups.

As TTM predominantly affects women (up to 94%; for review see Snorrason et al. 2012), our cohort comprised mainly

Table 1 Study sample characteristics and group differences

	TTM <i>n</i> = 29	CTRL <i>n</i> = 28	Group differences
Age, <i>MD</i> (range)	32 (18–63)	29 (18–56)	<i>U</i> = 329.5, <i>p</i> = 0.222
Gender, Female/Male	28/1	16/12	$\chi^2(1) = 12.57, p < 0.001$
Education level, <i>n</i> (%)			<i>U</i> = 394.5, <i>p</i> = 0.842
Grade 11/12	10 (35)	11 (39)	
College	7 (24)	3 (11)	
University	12 (41)	14 (50)	
Ethnicity, <i>n</i>			$\chi^2(1) = 5.29, p = 0.021$
Caucasian	24	28	
Other (Mixed, Black, Asian)	5	0	
Global grey matter volume in ml, <i>M</i> (<i>SD</i>)	673 (63)	698 (71)	<i>t</i> (55) = 1.38, <i>p</i> = 0.174
Global white matter volume in ml, <i>M</i> (<i>SD</i>)	515 (47)	538 (55)	<i>t</i> (55) = 1.71, <i>p</i> = 0.092
Cerebrospinal fluid volume in ml, <i>M</i> (<i>SD</i>)	300 (48)	315 (46)	<i>t</i> (55) = 1.18, <i>p</i> = 0.242
Age at onset of hair-pulling, <i>MD</i> (range)	13 (4–45)		
Illness duration in years, <i>MD</i> (range)	15 (2–49)		
Symptom severity measure			
MGH-HPS, <i>MD</i> (range)	17 (3–24)		
CGI-Severity, <i>MD</i> (range)	4 (1–6)		

CGI Clinical Global Impressions scale, MGH-HPS Massachusetts General Hospital Hairpulling Scale, *MD* median, *M* mean, *SD* standard deviation. Significant differences are highlighted in bold

female patients and one male. The median age of onset of TTM was early adolescence, with 86% of patients reporting onset before or at the age of 18. Four TTM patients met criteria for the secondary diagnosis of specific phobia, with one of those also meeting criteria for obsessive-compulsive personality disorder. Three patients were stabilized on selective serotonin reuptake inhibitor treatment at the time of MRI acquisition.

VBM group comparisons

The GLM revealed statistically significant volumetric group differences, with TTM patients presenting with larger white matter volumes in the parahippocampal gyrus and cerebellum, and reduced white matter volume in the postcentral gyrus, relative to CTRLs. See Table 2 for results meeting the empirically determined cluster extent threshold of 57 voxels. When comparing only participants with matching scanner parameters (TTM: $n = 17$, CTRL: $n = 28$), the finding of larger white matter volumes in the parahippocampal gyrus ($x, y, z = -32, 2, -22$; $n = 18$; $z = 4.81$; $p_{FWE \text{ cluster}} = 0.027$) and cerebellum ($x, y, z = 19, -75, -38$; $n = 29$; $z = 4.74$; $p_{FWE \text{ cluster}} = 0.021$) of TTM patients compared to CTRLs was confirmed, but not the smaller volume in the postcentral gyrus. This was also the case for the analysis including only female participants with the same scan parameters (parahippocampal gyrus: $x, y, z = -32, 1, -22$; $n = 321$; $z = 4.44$; and cerebellum: $x, y, z = 19, -74, -41$; $n = 415$; $z = 4.36$). Due to the reduced sample size of this follow-up analysis (TTM: $n = 17$, CTRL: $n = 16$), results are statistically significant at the uncorrected level $p < 0.0001$, meeting the empirically determined cluster extent threshold of 100 voxels.

In terms of grey matter volumes, no statistically significant differences were found between groups in the whole-brain analyses. An overview of grey matter group differences at an uncorrected $p < 0.0001$ can be found in the Supplementary Table 1.

VBM regression with hair-pulling severity scores

No significant associations were found between estimated white matter volumes (adjusted for age, TIV, and scan

parameters) and illness duration or MGH-HPS scores (total and factor scores for severity and resistance/control).

Examining the TTM group for associations of white matter volumes with various hair-pulling severity ratings of interest separately, which included level of control over pulling, frequency of pulling, associated distress, and attempts to resist pulling, we found significant associations between larger temporal and cerebellar white matter volumes and fewer attempts to resist hair-pulling (see Table 3 and Fig. 1). Results met the empirically determined cluster extent threshold of $n_{\text{voxels}} = 467$.

Discussion

The main findings of this study were larger white matter volumes in the left parahippocampal gyrus and right cerebellum in TTM compared to CTRLs. While there were no significant correlations with illness duration and total pulling severity scores, significant associations between larger white matter volumes and fewer attempts to resist hair-pulling were found in the right middle temporal gyrus, right cerebellum and left lingual gyrus of participants with TTM.

These results are consistent with emerging evidence for cerebellar involvement in TTM; previously, aberrations in cerebellar grey matter structure as well as metabolism have been reported (Keuthen et al. 2007a; Swedo et al. 1991). The cerebellum shares many bidirectional connections with cortical areas involved in the integration and coordination of sensorimotor information, language, affect and cognitive functioning; and cerebellar lesion studies have reported disturbances in these domains following disruptions in cortico-cerebellar connections (Baillieux et al. 2008, 2010). Hence, structural abnormalities and dysfunction in the cerebellum are not specific to TTM but may play a significant role in various psychiatric disorders, including autism, major depressive disorder, obsessive compulsive disorder (OCD), and schizophrenia (Romer et al. 2018; Stoodley 2016). We found larger white matter volumes in TTM versus CTRLs in the posterior cerebellum, including the posterior vermis (VIIb), pyramis (VIII) and uvula. These lobules have been suggested to be part of the

Table 2 Group comparisons for white matter estimates, adjusted for age and total intracranial volume

Brain region		MNI Coordinates			Cluster size (n voxels)	Z-statistic	P _{FWE} Cluster	P _{FWE} Peak
		x	y	z				
TTM > CTRL								
Parahippocampal gyrus	L	-38	-4	-15	157	5.13	0.005	0.005
Cerebellum VIII	R	18	-70	-39	94	4.88	0.009	0.015
TTM < CTRL								
Postcentral gyrus	R	18	-36	70	58	4.91	0.015	<0.001

L left hemisphere, R right hemisphere, FWE Family-wise error corrected

Table 3 Associations between larger white matter volumes and fewer attempts to resist hair-pulling

Brain region		MNI Coordinates			Cluster size (n voxels)	Z-statistic	PFWE Cluster	PFWE Peak
		x	y	z				
Middle temporal gyrus	R	51	−59	10	467	4.79	0.015	0.005
Cerebellum VIIb, VIII, CrusI	R	42	−51	−46	693	4.69	0.011	0.008
Lingual gyrus	L	−20	−52	−9	1244	4.51	0.005	0.015

L left hemisphere, R right hemisphere, FWE Family-wise error corrected

cognitive control network, showing strong connections with the prefrontal cortex (Keuthen et al. 2007; Romer et al. 2018). Our findings also indicated, when investigating the relationship between brain structure and TTM severity, a significant association between larger white matter volumes in the right middle temporal gyrus, left lingual gyrus, and right cerebellar hemispheric lobules VIIb, VIII, and crus I, and MGH-HPS scores on resistance to hair-pulling, with higher scores indicating higher TTM severity and fewer attempts to resist the urge to pull.

Activity in the posterior vermis has previously been associated with drug craving and the processing of drug-related cues (in nearly all types of addictive drugs), this suggests a possible link between TTM and substance use disorders, consistent with the hypothesis that both substance use disorders and OCRDs involve both compulsivity and impulsivity (Flessner et al. 2012; Moreno-Rius and Miquel 2017).

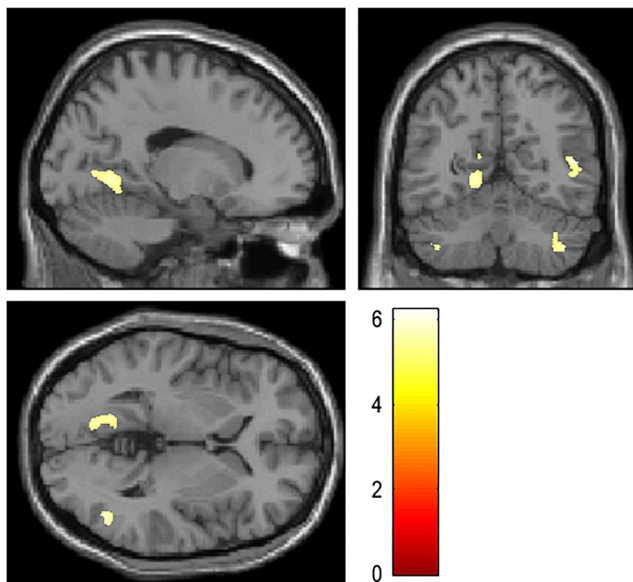


Fig. 1 Sagittal, coronal and axial slices illustrating a positive multiple regression in the trichotillomania (TTM) group, with fewer attempts to resist hair-pulling as covariate of interest, and age, total intracranial volume, and differences in scan parameters as covariates of no interest. Significant clusters (for details see Table 3) are corrected for multiple comparisons at the family-wise error $p = 0.05$. The colour bar represents z-statistic

Several areas of the cerebellum (e.g. lobule VI, crus I and II, and the posterior vermis VIIb) have been suggested to play a substantial role in addiction processes, particularly, the unconscious prediction of drug availability and reward when presented with a drug cue, and interestingly, higher activity in the vermis in response to cues has been linked to relapse in heroin addicts (Miquel et al. 2016; Moreno-Rius and Miquel 2017; Moulton et al. 2014). Additionally, the cerebellar vermis facilitates input integration from various brain regions with the aim of encoding the primary affective and motivational aspects of the cue to inform the response (Moreno-Rius and Miquel 2017). According to this perspective, cue exposure (e.g. an idea or image which relates to hair-pulling) would result in the development of an imagined anticipatory scenario (i.e. the kind one might implicate in focused pulling in TTM) aiding the response selection, or the priming or activation of brain regions associated with substance seeking and consummatory behaviors. This is arguably consistent with recent suggestions that cerebellar structures (particularly the vermis) are implicated in the disrupted reward processes involved in impulse control disorders (e.g. substance or behavioral addictions) and disorders on the compulsive spectrum (e.g. binge eating disorders) (Flessner et al. 2012; Moreno-Rius and Miquel 2017).

Fewer attempts to resist hair-pulling also correlated with larger white matter volumes in the lingual gyrus, and structural alterations in this brain area have previously been linked to dysregulated cognition and emotion (Romer et al. 2018). The lingual gyrus has also been implicated in inhibitory processes, such as top-down cognitive control or motor inhibition (Menon et al. 2001; Zhang et al. 2016). In addition to deficits in motor inhibition in TTM (Chamberlain et al. 2006), greater lingual grey matter volume or thickness were reported in patients and unaffected relatives (Grachev 1997; Odlaug et al. 2014). The observed brain behavior relationships in the current study suggest that white matter alterations may represent maladaptive reorganization of sensorimotor and cognitive processing networks relative to TTM severity. That said, we did not find significant correlations with MGH-HPS total scores and factor scores for severity and resistance/control.

We further found larger white matter volumes in TTM in the left parahippocampal gyrus, a region in which our

group previously reported lower cortical thickness compared to CTRLs (Roos et al. 2015). As part of the limbic lobe, the parahippocampal gyrus receives input from widespread visual, somatosensory, auditory, and higher order multimodal association areas, and serves as an interface between the hippocampus and neocortex, and the amygdala (Suzuki 2009). With its functional involvement in encoding memories and forming associations, the parahippocampal gyrus may play a role in various psychopathologies, including dissociative disorder (Ehling et al. 2008). Dissociative experiences are also often reported by patients with TTM and OCD (Lochner et al. 2004) or substance use disorders (Schäfer et al. 2010). The parahippocampus is further part of a brain network associated with internally-focused mental processes, and previous research has suggested greater activity and connectivity in this network contributing to the symptomatology in OCD (Stern et al. 2013).

TTM patients often use tactile cues to identify hair-pulling targets and the sensory experience of the hair being pulled converts initial tension to a state of relief or gratification. A previous DTI study found diminished microstructural integrity of white matter tracts in a network including the somatosensory brain region, responsible for motor generation and suppression as well as emotional processing (Chamberlain et al. 2010). The present study reports smaller white matter volume in the postcentral gyrus/primary somatosensory cortex, where the majority of somatosensory information is processed. However, this finding should be interpreted with caution, as it could not be confirmed with follow-up tests in subgroups.

Contrary to our hypothesis, we did not find statistically significant volumetric changes in fronto-striatal structures in TTM compared to CTRLs. In addition to previous research reporting inconsistent grey and white matter findings in this circuit (Chamberlain et al. 2010, 2018; Grachev 1997; Isobe et al. 2018; Odlaug et al. 2014; O’Sullivan et al. 1997; Roos et al. 2013; Stein et al. 1997), functional neuroimaging could not provide evidence for cortico-striatal dysfunction in TTM during a serial reaction time task (Rauch et al. 2007). Such inconsistencies in brain imaging findings may have different origins, for example, in the (non-)matching of study groups, exclusion of comorbidities, choice of smoothing kernel size, scanner magnet strength, and severity of disorder. It should also be noted that in psychiatry research, sample size may be small and thus limiting. Hence, international consortia and multi-site projects that combine data from different sites are important. The merit of analysing pooled data in a harmonized way is obvious, especially concerning the enhanced power due to larger sample sizes. However, pooling data from different research sites may bear additional confounds. While there is an ongoing debate on the potential influences of acquisition parameters and scan sequences on brain structure

analyses (as might be the case in the present study), the effects are generally considered minimal (Chen et al. 2014; Jovicich et al. 2009), and international multi-site analyses do not necessarily adjust for these effects (Isobe et al. 2018). Additionally, the application of different imaging analysis tools or pipelines (the most commonly used pipelines being FSL, Freesurfer and SPM) may result in varying outcome (Fellhauer et al. 2015). This, for example, was the case in the two analyses of the first pooled multi-site sample in TTM (both included about half of the participants of the present study; Chamberlain et al. 2018; Isobe et al. 2018), where a Freesurfer and a FSL analysis of subcortical structures did not reveal the same significant results despite the overlapping data. As a possible explanation, it has been reported that some of the variability in reported research findings may stem from differences in sensitivity and accuracy of the various analysis pipeline algorithms for grey matter, white matter or subcortical structures (Eggert et al. 2012). Such inconsistencies call for more harmonised processing protocols to reveal differences in particular brain structures in a given neuropsychiatric condition. Lastly, we may gain a better idea of brain abnormalities in mental disorders from using a multimodal approach rather than isolated methods and measures, as was most common in past psychiatry research.

Several limitations should be considered in the present study. The cross-sectional study design does not allow for inferences about the observed white matter structural aberrations constituting cause or effect of the disorder. Further, the reported abnormalities in TTM may have, to some extent, been confounded by effects of current and past medical treatment. However, due to the small number of medicated participants, such effects could not be evaluated. The observation that grey matter differences between TTM and CTRLs are statistically non-significant in the current study may suggest that sample size was too small to detect alterations in this brain substrate of individuals with TTM using VBM. Finally, by pooling scans with minor differences in scan parameters from two research sites in Cape Town, additional variation and confounds may have been introduced to the data. Yet, follow-up analyses including only participants with matching scanner parameters did confirm our cerebellar and parahippocampal findings. Gender distribution, especially in the control group, was a further limitation to the study. Additional follow-up analyses (Allegra 3 T only/female only) confirmed that cerebellar and parahippocampal findings were not due to the gender differences (however, only at uncorrected level $p < 0.0001$ as power was limited for a valid subgroup comparison). Another potential limitation is the group difference in terms of ethnicity; however, the group difference in this regard did not hold for the follow-up analyses in the smaller subset, and was thus not further addressed in the analyses.

In conclusion, the pathophysiology of TTM involves multiple neural pathways. Impairments in cortico-cerebellar

communication may lead to reduced ability to control hair-pulling behavior. Taken together, our observations suggest abnormalities in cerebral and cerebellar white matter subserving the somatosensory, memory, higher order association, and cognitive function domains in TTM patients. Future explorations of the relationship between localized structural abnormalities in white matter and the mediated functional domains are needed.

Acknowledgements This study was supported by the National Research Foundation (NRF) of South Africa (grant number CPRR15062211995). Dr. Uhlmann received a Stellenbosch University Subcommittee C post-doctoral fellowship.

Funding This study was funded by the National Research Foundation (NRF) of South Africa (grant number CPRR15062211995).

Compliance with ethical standards

Conflict of interest Author DJS has received research grants and/or consultancy honoraria from Abbott, ABMRF, Astrazeneca, Biocodex, Eli-Lilly, GlaxoSmithKline, Jazz Pharmaceuticals, Johnson & Johnson, Lundbeck, National Responsible Gambling Foundation, Novartis, Orion, Pfizer, Pharmacia, Roche, Servier, Solvay, Sumitomo, Sun, Takeda, Tikvah, and Wyeth.

The other authors declare no conflict of interest with respect to subjects of the paper.

Ethical approval All procedures performed in studies involving human participants were in accordance with the ethical standards of the institutional and/or national research committee and with the 1964 Helsinki declaration and its later amendments or comparable ethical standards.

Informed consent Informed consent was obtained from all individual participants included in the study.

References

- American Psychiatric Association. (2013). *Diagnostic and statistical manual of mental disorders* (5th ed.). Washington, DC: Author.
- Ashburner, J. (2007). A fast diffeomorphic image registration algorithm. *Neuroimage*, 38(1), 95–113.
- Baillieux, H., De Smet, H. J., Paquier, P. F., De Deyn, P. P., & Mariën, P. (2008). Cerebellar neurocognition: Insights into the bottom of the brain. *Clinical Neurology and Neurosurgery*, 110(8), 763–773.
- Baillieux, H., De Smet, H. J., Dobbeleir, A., Paquier, P. F., De Deyn, P. P., & Mariën, P. (2010). Cognitive and affective disturbances following focal cerebellar damage in adults: a neuropsychological and SPECT study. *Cortex*, 46(7), 869–879.
- Busner, J., & Targum, S. D. (2007). The clinical global impressions scale: applying a research tool in clinical practice. *Psychiatry (Edgmont)*, 4(7), 28–37.
- Chamberlain, S. R., Fineberg, N. A., Blackwell, A. D., Robbins, T. W., & Sahakian, B. J. (2006). Motor inhibition and cognitive flexibility in obsessive-compulsive disorder and trichotillomania. *The American Journal of Psychiatry*, 163(7), 1282–1284.
- Chamberlain, S. R., Menzies, L. A., Fineberg, N. A., del Campo, N., Suckling, J., Craig, K., Müller, U., Robbins, T. W., Bullmore, E. T., & Sahakian, B. J. (2008). Grey matter abnormalities in trichotillomania: morphometric magnetic resonance imaging study. *The British Journal of Psychiatry*, 193, 216–221.
- Chamberlain, S. R., Hampshire, A., Menzies, L. A., Garyfallidis, E., Grant, J. E., Odlaug, B. L., Craig, K., Fineberg, N., & Sahakian, B. J. (2010). Reduced brain white matter integrity in trichotillomania: a diffusion tensor imaging study. *Archives of General Psychiatry*, 67, 965–971.
- Chamberlain, S. R., Harries, M., Redden, S. A., Keuthen, N. J., Stein, D. J., Lochner, C., & Grant, J. E. (2018). Cortical thickness abnormalities in trichotillomania: International multi-site analysis. *Brain Imaging and Behavior*. <https://doi.org/10.1007/s11682-017-9746-3>.
- Chen, J., Liu, J., Calhoun, V. D., Arias-Vasquez, A., Zwiers, M. P., Gupta, C. N., Franke, B., & Turner, J. A. (2014). Exploration of scanning effects in multi-site structural MRI studies. *Journal of Neuroscience Methods*, 230, 37–50.
- du Toit, P. L., van Kradenburg, J., Niehaus, D., & Stein, D. J. (2001). Comparison of obsessive-compulsive disorder patients with and without comorbid putative obsessive-compulsive spectrum disorders using a structured clinical interview. *Comprehensive Psychiatry*, 42(4), 291–300.
- Eggert, L. D., Sommer, J., Jansen, A., Kircher, T., & Konrad, C. (2012). Accuracy and reliability of automated gray matter segmentation pathways on real and simulated structural magnetic resonance images of the human brain. *PLoS One*, 7(9), e45081.
- Ehling, T., Nijenhuis, E. R., & Krikke, A. P. (2008). Volume of discrete brain structures in complex dissociative disorders: preliminary findings. *Progress in Brain Research*, 167, 307–310.
- Fellhauer, I., Zöllner, F. G., J Schröder, J., Degen, C., Kong, L., Essig, M., Thomann, P. A., & Schad, L. R. (2015). Comparison of automated brain segmentation using a brain phantom and patients with early Alzheimer's dementia or mild cognitive impairment. *Psychiatry Research: Neuroimaging*, 233(3), 299–305.
- Flessner, C. A., Knopik, V. S., & McGeary, J. (2012). Hair pulling disorder (trichotillomania): genes, neurobiology, and a model for understanding impulsivity and compulsivity. *Psychiatry Research*, 199, 151e158.
- Grachev, I. D. (1997). MRI-based morphometric topographic parcellation of human neocortex in trichotillomania. *Psychiatry and Clinical Neurosciences*, 51, 315–321.
- Grant, J. E., & Chamberlain, S. R. (2016). Trichotillomania. *The American Journal of Psychiatry*, 173(9), 868–873.
- Isobe, M., Redden, S. A., Keuthen, N. J., Stein, D. J., Lochner, C., Grant, J. E., & Chamberlain, S. R. (2018). Striatal abnormalities in trichotillomania: a multi-site MRI analysis. *NeuroImage: Clinical*, 17, 893–898.
- Jovicich, J., Czanner, S., Han, X., Salat, D., van der Kouwe, A., Quinn, B., Pacheco, J., Albert, M., Killiany, R., Blacker, D., Maguire, P., Rosas, D., Makris, N., Gollub, R., Dale, A., Dickerson, B. C., & Fischl, B. (2009). MRI-derived measurements of human subcortical, ventricular and intracranial brain volumes: Reliability effects of scan sessions, acquisition sequences, data analyses, scanner upgrade, scanner vendors and field strengths. *NeuroImage*, 46(1), 177–192.
- Keuthen, N. J., O'Sullivan, R. L., Ricciardi, J. N., Shera, D., Savage, C. R., Borgmann, A. S., Jenike, M. A., & Baer, L. (1995). The Massachusetts General Hospital (MGH) Hairpulling scale, 1: development and factor analyses. *Psychotherapy and Psychosomatics*, 64, 141–145.
- Keuthen, N. J., Makris, N., Schlerf, J. E., Martis, B., Savage, C. R., McMullin, K., Seidman, L. J., Schmahmann, J. D., Kennedy, D. N., Hodge, S. M., & Rauch, S. L. (2007a). Evidence for reduced cerebellar volumes in trichotillomania. *Biological Psychiatry*, 61, 374–381.
- Keuthen, N. J., Flessner, C. A., Woods, D. W., Franklin, M. E., Stein, D. J., & Cashin, S. E. (2007b). Factor analysis of the Massachusetts General Hospital Hairpulling scale. *Journal of Psychosomatic Research*, 62(6), 707–709.

- Lochner, C., Seedat, S., Hemmings, S. M., Kinnear, C. J., Corfield, V. A., Niehaus, D. J., Moolman-Smook, J. C., & Stein, D. J. (2004). Dissociative experiences in obsessive-compulsive disorder and trichotillomania: Clinical and genetic findings. *Comprehensive Psychiatry*, *45*(5), 384–391.
- Menon, V., Adelman, N. E., White, C. D., Glover, G. H., & Reiss, A. L. (2001). Error-related brain activation during a Go/NoGo response inhibition task. *Human Brain Mapping*, *12*(3), 131–143.
- Miquel, M., Vazquez-Sanroman, D., Carbo-Gas, M., Gil-Miravet, I., Sanchis-Segura, C., Carulli, D., Manzo, J., & Coria-Avila, G. A. (2016). Have we been ignoring the elephant in the room? Seven arguments for considering the cerebellum as part of addiction circuitry. *Neuroscience & Biobehavioral Reviews*, *60*, 1–11.
- Moreno-Rius, J., & Miquel, M. (2017). The cerebellum in drug craving. *Drug and Alcohol Dependence*, *173*, 151–158.
- Moulton, E. A., Elman, I., Becerra, L. R., Goldstein, R. Z., & Borsook, D. (2014). The cerebellum and addiction: insights gained from neuroimaging research. *Addiction Biology*, *19*(3), 317–331.
- O’Sullivan, R. L., Rauch, S. L., Breiter, H. C., Grachev, I. D., Baer, L., Kennedy, D. N., Keuthen, N. J., Savage, C. R., Manzo, P. A., Caviness, V. S., & Jenike, M. A. (1997). Reduced basal ganglia volumes in trichotillomania measured via morphometric magnetic resonance imaging. *Biological Psychiatry*, *42*, 39–45.
- Odlaug, B. L., Chamberlain, S. R., Derbyshire, K. L., Leppink, E. W., & Grant, J. E. (2014). Impaired response inhibition and excess cortical thickness as candidate endophenotypes for trichotillomania. *Journal of Psychiatry Research*, *59*, 167–173.
- Rauch, S. L., Wright, C. I., Savage, C. R., Martis, B., McMullin, K. G., Wedig, M. M., Gold, A. L., & Keuthen, N. J. (2007). Brain activation during implicit sequence learning in individuals with trichotillomania. *Psychiatry Research: Neuroimaging*, *154*(3), 233–240.
- Romer, A. L., Knodt, A. R., Houts, R., Brigidi, B. D., Moffitt, T. E., Caspi, A., & Hariri, A. R. (2018). Structural alterations within cerebellar circuitry are associated with general liability for common mental disorders. *Molecular Psychiatry*, *23*(4), 1084–1090.
- Roos, A., Fouche, J. P., Stein, D. J., & Lochner, C. (2013). White matter integrity in hairpulling disorder (trichotillomania). *Psychiatry Research: Neuroimaging*, *211*, 246–250.
- Roos, A., Grant, J. E., Fouche, J. P., Stein, D. J., & Lochner, C. (2015). A comparison of brain volume and cortical thickness in excoriation (skin picking) disorder and trichotillomania (hair pulling disorder) in women. *Behavioural Brain Research*, *279*, 255–258.
- Schäfer, I., Langeland, W., Hissbach, J., Luedecke, C., Ohlmeier, M. D., Chodzinski, C., Kemper, U., Keiper, P., Wedekind, D., Havemann-Reinecke, U., Teunissen, S., Weirich, S., & Driessen, M. (2010). Childhood trauma and dissociation in patients with alcohol dependence, drug dependence, or both—a multi-center study. *Drug and Alcohol Dependence*, *109*(1–3), 84–89.
- Sheehan, D. V., Lecrubier, Y., Sheehan, K. H., Amorim, P., Janavs, J., Weiller, E., Hergueta, T., Baker, R., & Dunbar, G. C. (1998). The mini-international neuropsychiatric interview (M.I.N.I.): the development and validation of a structured diagnostic psychiatric interview for DSM-IV and ICD-10. *The Journal of Clinical Psychiatry*, *59*(Suppl 20), 22–33.
- Snorrason, I., Belleau, E. L., & Woods, D. W. (2012). How related are hair pulling disorder (trichotillomania) and skin picking disorder? A review of evidence for comorbidity, similarities and shared etiology. *Clinical Psychology Review*, *32*(7), 618–629.
- Stein, D. J., Coetzer, R., Lee, M., Davids, B., & Bouwer, C. (1997). Magnetic resonance brain imaging in women with obsessive-compulsive disorder and trichotillomania. *Psychiatry Research*, *74*, 177–182.
- Stein, D. J., Chamberlain, S. R., & Fineberg, N. A. (2006). An A-B-C model of habit disorders: hair-pulling, skin-picking, and other stereotypic conditions. *CNS Spectrums*, *11*(11), 824e7.
- Stern, E. R., Welsh, R. C., Gonzalez, R., Fitzgerald, K. D., Abelson, J. L., & Taylor, S. F. (2013). Subjective uncertainty and limbic hyperactivation in obsessive-compulsive disorder. *Human Brain Mapping*, *34*(8), 1956–1970.
- Stoodley, C. J. (2016). The cerebellum and neurodevelopmental disorders. *The Cerebellum*, *15*(1), 34–37.
- Suzuki, W. A. (2009). Declarative memory system: Anatomy. In L. R. Squire (Ed.), *Encyclopedia of neuroscience* (pp. 347–356). Oxford: Academic Press.
- Swedo, S. E., Rapoport, J. L., Leonard, H. L., Schapiro, M. B., Rapoport, S. I., & Grady, C. L. (1991). Regional cerebral glucose metabolism of women with trichotillomania. *Archives of General Psychiatry*, *48*(9), 828–833.
- Woods, D. W., Flessner, C. A., Franklin, M. E., Keuthen, N. J., Goodwin, R. D., Stein, D. J., & Walther, M. R. (2006). The trichotillomania impact project (TIP): exploring phenomenology, functional impairment, and treatment utilization. *The Journal of Clinical Psychiatry*, *67*, 1877–1888.
- Zhang, L., Qiao, L., Chen, Q., Yang, W., Xu, M., Yao, X., Qiu, J., & Yang, D. (2016). Gray matter volume of the lingual gyrus mediates the relationship between inhibition function and divergent thinking. *Frontiers in Psychology*, *7*, 1532.

Publisher’s note Springer Nature remains neutral with regard to jurisdictional claims in published maps and institutional affiliations.